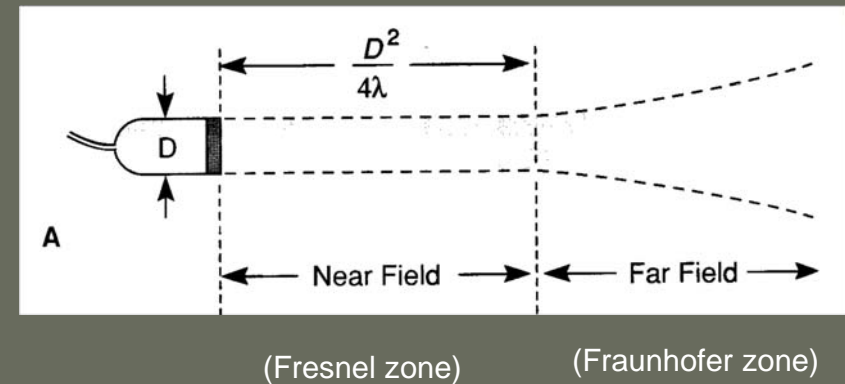


(ULTRA)SONOGRAPHY 2013

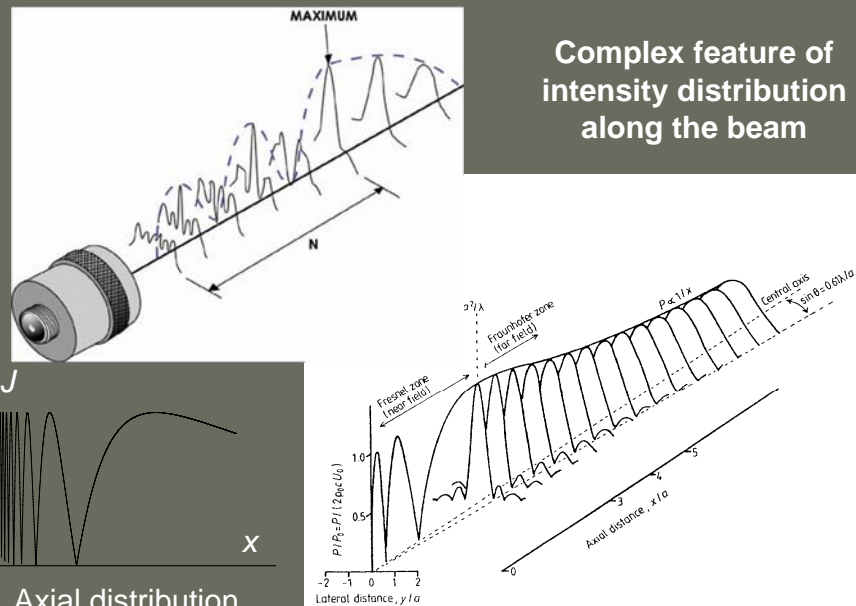
CONTINUATION:

A-mode visualization, B-mode: Imaging

Simplified view of an
ultrasound beam

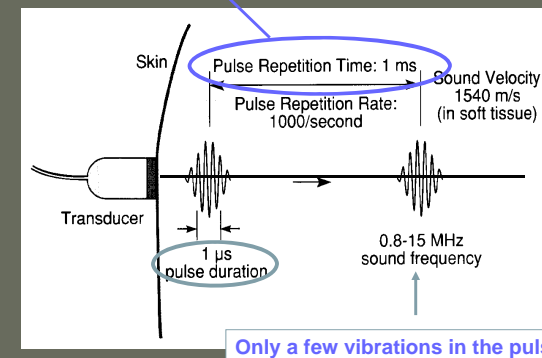


Complex feature of
intensity distribution
along the beam



Long pause between **short** pulses allows the detection of
reflected pulses

How far does an US pulse (of $1 \mu\text{s}$ duration) propagate
in muscle ($c=1500 \text{ m/s}$) within 1 ms ?



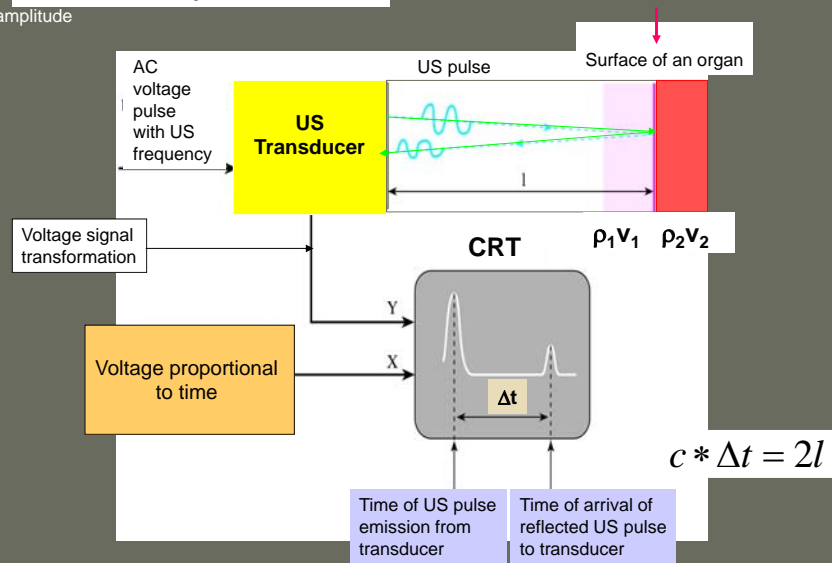
$d = 1.5 \text{ m} !$

size of the
human body

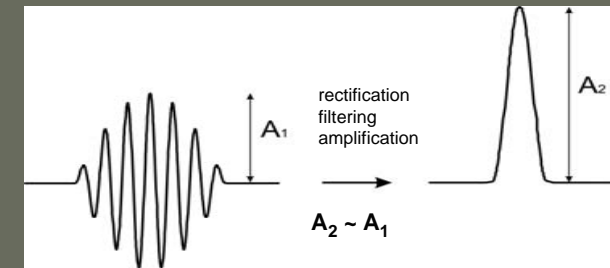
Only a few vibrations in the pulse

A – mode pulse echo

amplitude



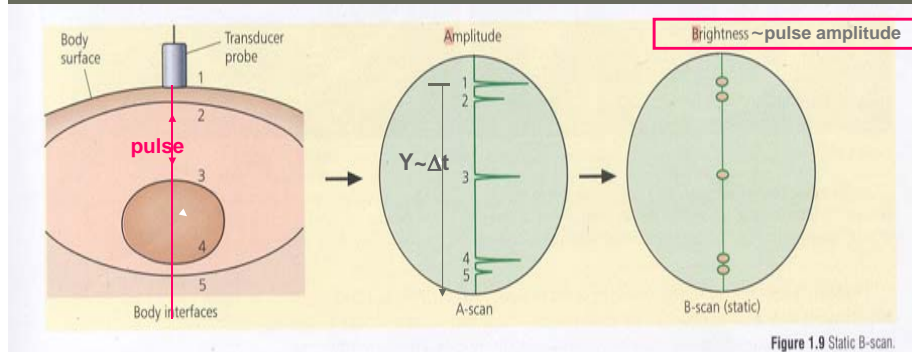
Voltage signal transformation



Voltage pulse generated in the transducer by the received reflected ultrasound pulse

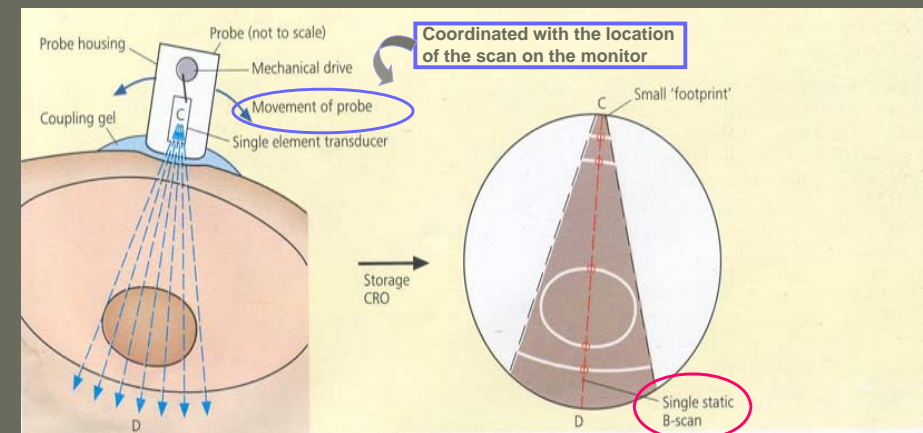
Voltage pulse connected to the Y axis of the monitor

A – scan transformed into B- scan



Linear static
B-scan

Series of B-mode linear scans in a sectional plane yield an ultrasound tomogram



In ultrasound imaging the sites of US pulse reflection are visualized in a selected section

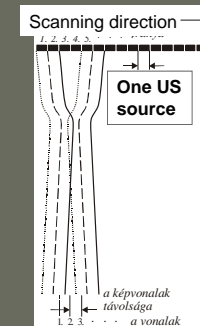
Bright detail – strong reflection (low absorption)

2D images are produced by a series of linear B-scans

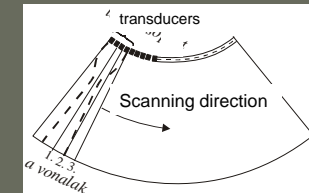
Scanning methods

Transducer **arrays**: hundreds of piezoelectric elements

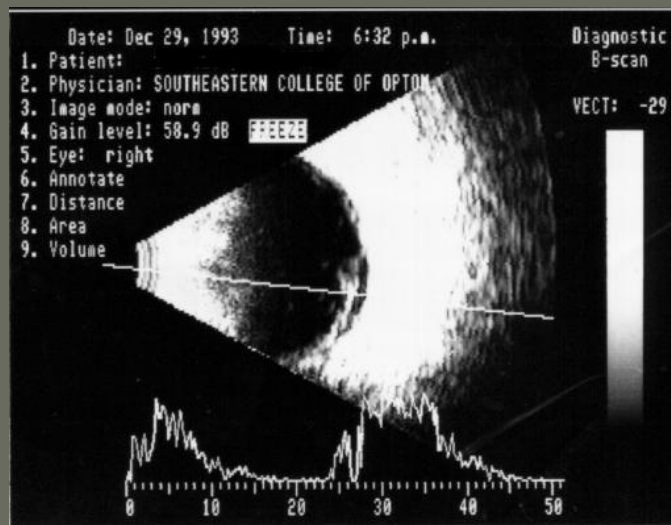
“linear array”



“curved array” or convex array : image is fan-shaped



2-dimensional B-mode and A-mode (used in ophthalmology)



real speed of propagation for the accurate determination of distances:

cornea: 1641 m/s

aqueous humour: 1532 m/s

crystalline lens: 1641 m/s

vitreous body: 1532 m/s

Brightness of US tomograms is determined by the reflection coefficient (= „echo”) of internal boundary and by the absorption of the tissues

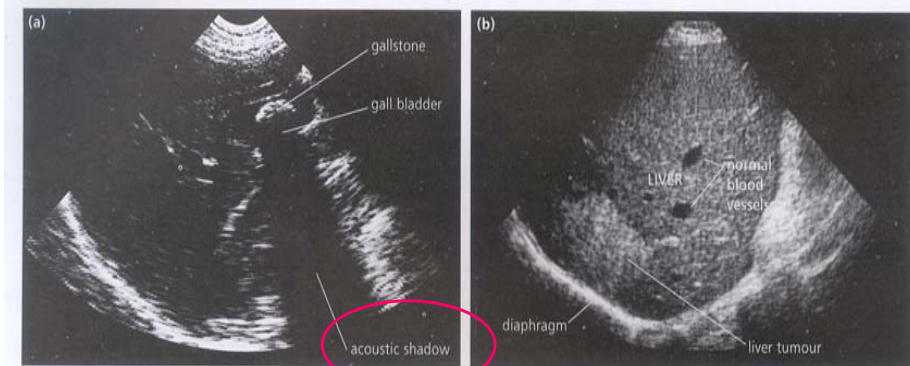
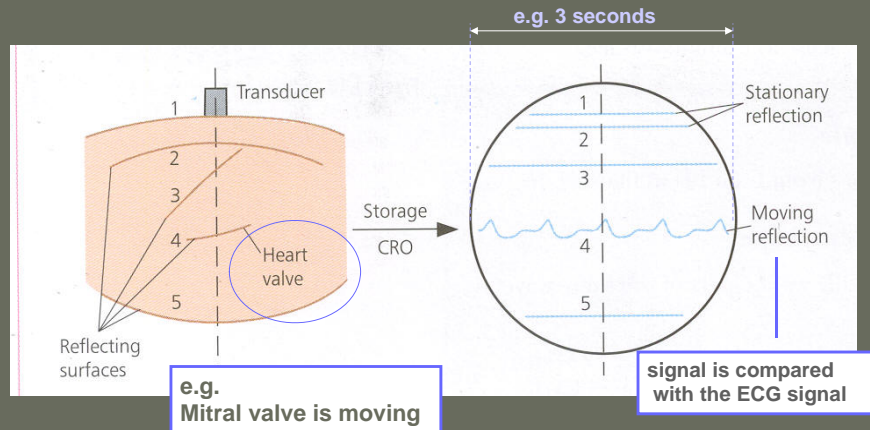


Figure 1.11 The B-scan is essentially a ‘white on black’ image: strong echoes produce white areas, while echo-free regions are black. For example, fluid-filled structures, like the gall bladder (a), produce large echoes from their walls, which consequently appear white, but no echoes from the fluid contained within them, which thus looks black. In this example, the strong echo-producing stone appears white, and in fact creates an ‘acoustic shadow’ beyond it (see page 18). In (b), the contrast between the light appearance of the diaphragm and liver tumour (strong echoes), the grey liver tissue (some echoes), and the black cross-sections of normal blood vessels (no echoes), is clear.

White on black images

TM-scan

„Motion” is visualized. A static B-scan is taken several times and shown shifted in time along with the X-axis of CRO.



TM-kép

B-kép

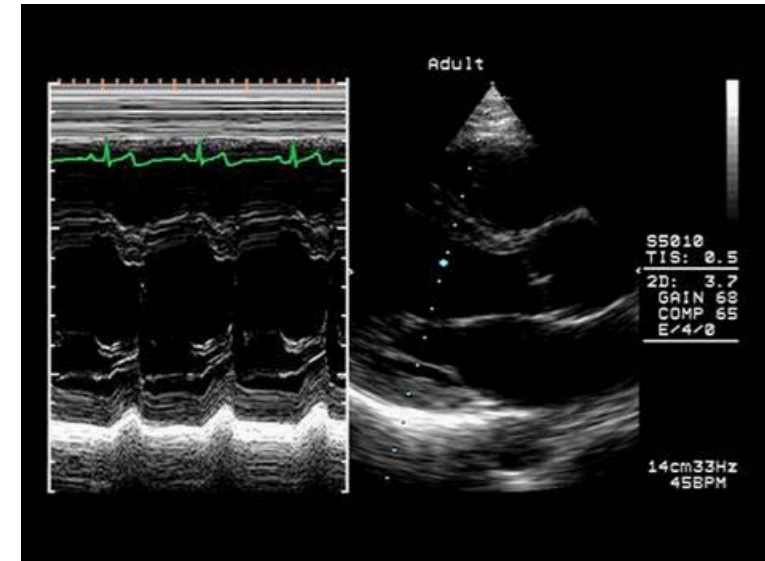
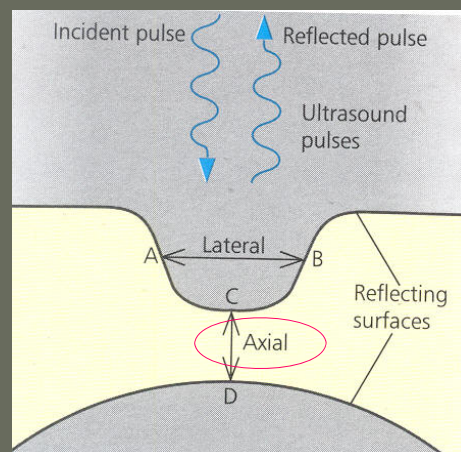


Image clarity – resolution

ability of the beam to detect two objects as separate

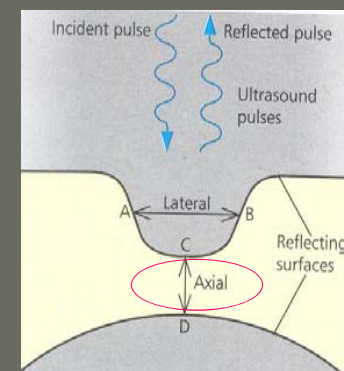


Axial (=depth) resolution
= Distance CD

Depends on pulse duration
The shorter the better

$CD > \frac{1}{2} \text{ pulse length}$

Axial resolution



Example:

12 MHz, soft tissue ($c=1500$ m/s)

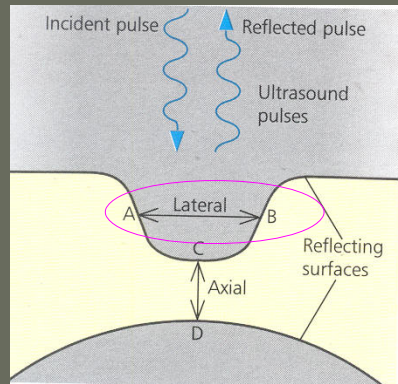
3 periods in one pulse

Pulse length = $c \times \text{pulse duration}$
= $375 \mu\text{m}$

Distance CD $> 188 \mu\text{m}$

Image clarity – Lateral resolution

Details at right angles to the beam: A to B



Good conditions:

- High frequency -> less scattering
- Narrow beam -> focusing



Absorbed more!
Compromise!
Common: 3 - 10 MHz

\overline{AB} is $\sim 10 \times$ axial resolution

Role of US frequency in applications

Frequency (MHz)	Penetration depth (cm)	Resolution (mm)	Application
3-5	10 -20	1.0	deep: heart, uterus, liver
4-10	5	0.2	quite superficial: thyroid, breast, carotid artery
10-15	1	0.1	very superficial: eye
50 (special methods)	few mm	0.05	skin, blood vessel walls

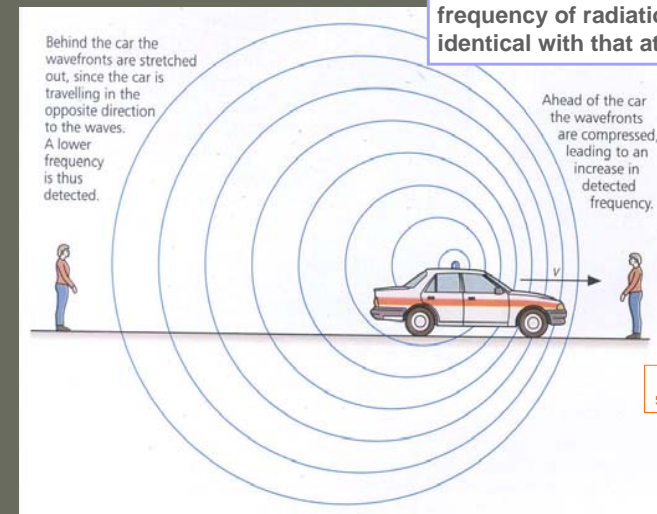
Fields of applying US pulse-echo imaging

- **Obstetrics**
monitoring of fetal development
- **Abdominal investigations**
excellent soft tissue discrimination: liver, kidney, pancreas
- **Ultrasound cardiography (UCG)**
lung: presence of air reflects US
but: **sectional B-scans** are possible through a small window in the chest wall

Considerable experience is needed

Doppler methods

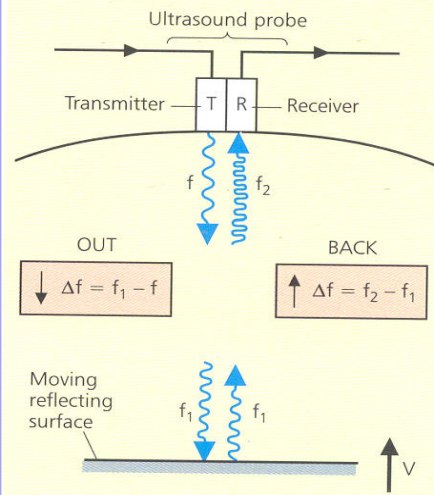
Doppler effect:
when there is relative motion between source and observer, the observed frequency of radiation will not be identical with that at the source



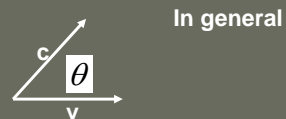
Δf
frequency change due to relative motion

„Doppler shift”

V and C are parallel



Doppler shift



In general

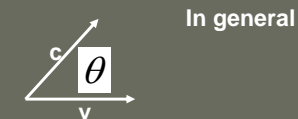
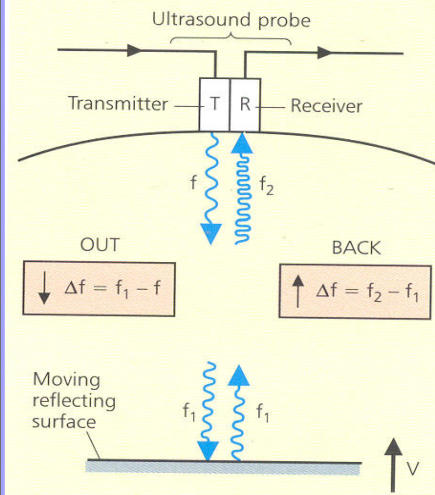
v is the speed of relative motion

Δf can be positive or negative

depending on the relative direction of **v** and **c**

Doppler shift

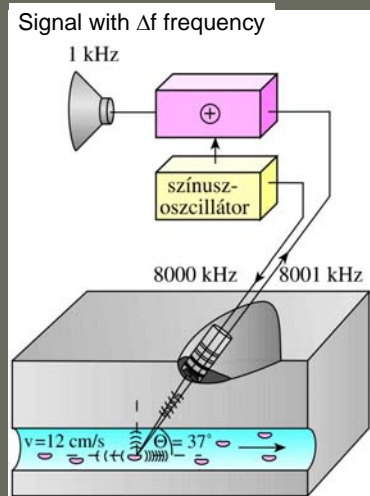
V and C are parallel



In reflection, the Doppler effect is duplicated

$$\Delta f = \pm \frac{2 * f * v}{c} \text{ „Doppler shift”}$$

The Doppler method is based on the effect of blood flow on the reflected frequency



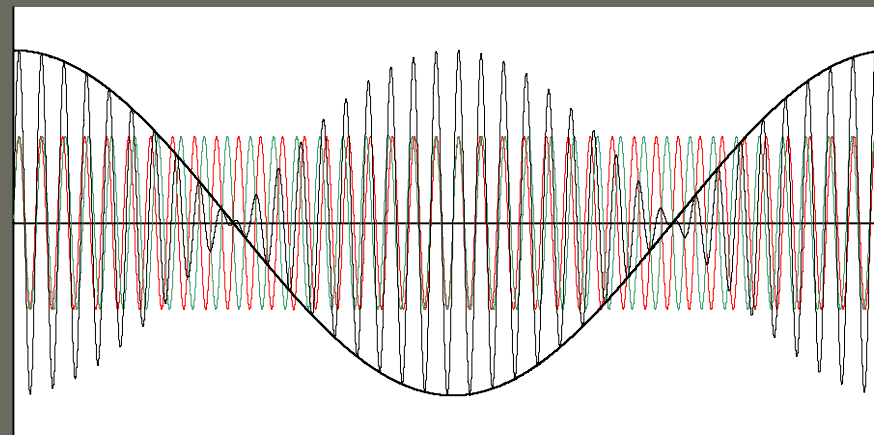
$$\Delta f = \pm \frac{2 * f * v * \cos \theta}{c}$$

Since **v** is small, **Δf** is small

Result of interference

$$f_{\text{red}} \geq f_{\text{green}}$$

Amplitude is changing with $f = f_r - f_g$



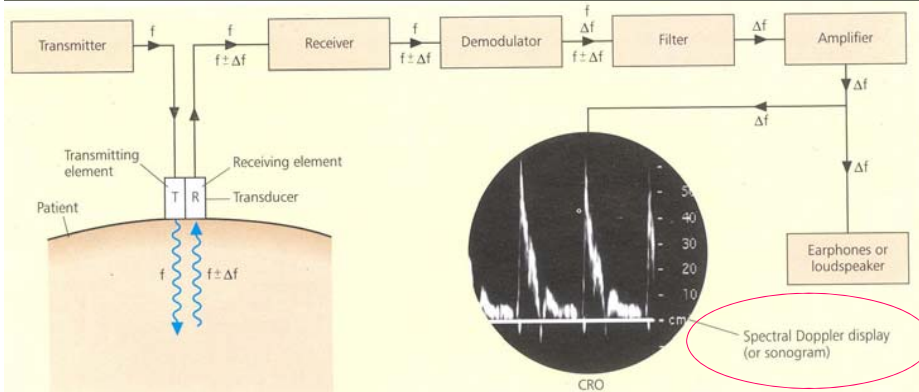
reminder

$$\sin \alpha + \sin \beta = 2 \sin \frac{\alpha + \beta}{2} \cos \frac{\alpha - \beta}{2}$$

Continuous wave Doppler system to measure spectral Doppler displays or sonograms

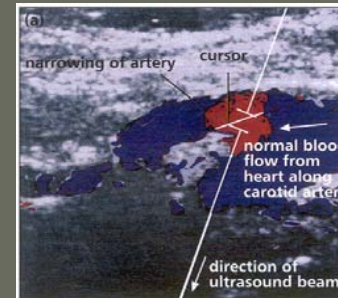
V of moving object is measured by determining Δf of Doppler shift

$$\Delta f = \pm \frac{2 * f * v}{c}$$



Since V is small, Δf is small \longrightarrow sound wave in the audible range

Blood flow measurement

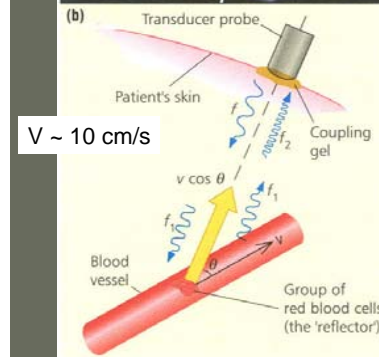


Example: in the region selected by the cursor, a narrowing causes reverse flow shown in red

General formula of Doppler shift

$$\Delta f = \frac{2 * f * v * \cos \theta}{c}$$

Reflecting particles do not move parallel with the ultrasound beam, but the angle can be measured on a regular B-scan



Color Doppler

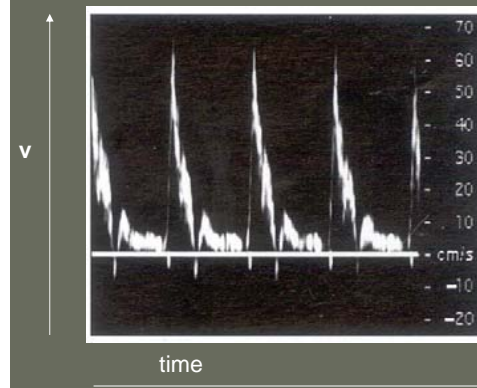
the sign of Δf shows the direction of the flow
 \rightarrow Shown by color coding

flow **towards** source: **red**

flow **away** source: **blue**

Blue Away Red Towards = BART

Spectral Doppler display determined in a region selected by the cursor



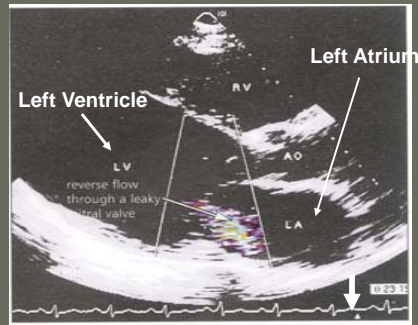
Brightness measures the Amplitude of reflected signal

Friction leads to a spread in the velocity of flowing particles

Blood flow shows pulsation – Usually compared to a ECG trace

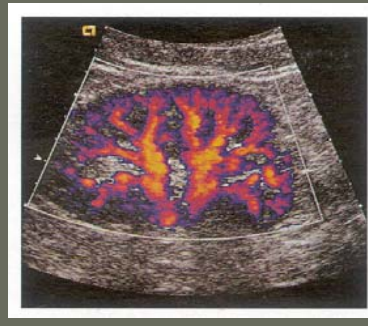Modern technique: Pulsed wave Doppler systems

- real time B-mode image
- color overlay of mean velocities
- separate spectral Doppler display



Color Doppler Flow imaging

Real time visualization of flow velocities
(see arrow on ECG signal)



Kidney: abnormal blood flow patterns

Applications of Color Doppler imaging

- Fetal heart monitoring
heart beat control during pregnancy and delivery
ultrasonic stethoscope
- Adult cardiology
performance of heart valves, blockages and holes in the heart,
leaky or constricted valves, motion of heart
- Blood circulation
narrowing or hardening of arteries, turbulent flow, thrombosis,
carotid artery, blood flow in abdominal organs

Intensity levels and biological effects

Procedure	Typical Intensity (Wm^{-2})	Beam type	Exposure time	Effect (ΔT = increase in tissue temperature)
diagnosis	10–30	Doppler: continuous	several minutes	negligible
	$10-10^4$	pulsed	several minutes	$\Delta T \leq 1^\circ\text{C}$ generally Caution at high intensities
physiotherapy	10^4	continuous	10–30 min	gentle ($\Delta T \sim 5^\circ\text{C}$) 'deep heat' (hyperthermia)
surgery	10^6	focused multiple beams	0.1–10 s	$\Delta T \sim 30 \rightarrow 50^\circ\text{C}$ Tissue damage or total destruction

+
Mechanical Effects
Cavity formation



The END